

# MARUTHUVA VIVEKAM

Doctors Advice - For a Healthier Life




*"I can see my baby!"*

Ultramodern Ultrasounds

*Stop that Stroke  
Starve that Tumour  
New non-surgical  
procedures*

Jan 2007 Vol:7

## FINDING A TUMOUR



**THE SIZE OF A PIN**

Advances in Imaging Sciences and how you can benefit



# From the Chairman's Desk



Dear friends,

Technology has made rapid strides in medicine. There has been a bewildering amount of scanning equipment, MRI's and other diagnostic equipment that have been launched recently, and are changing the way medicine is practised.

We now have CT scans that can pinpoint a tumour the size of a pin, nuclear scans that help us study organ function in a 3-day old baby, imaging equipment that enables us to visualise complex surgeries before they are performed. In fact, through the use of

imaging guidance several procedures can be performed by an Interventional Radiologist which earlier required surgery.


In this issue we have tried to "demystify" the latest in medical technology. Find out how you can benefit from a nuclear scan or how a 4D ultrasound can help you visualise a baby.

Please feel free to mail me with queries or feedback.

Wishing you a Happy and Healthy New Year!

Mrs. Mallika Mohandas  
Chairman, MIOT Hospitals

## Laughter is the Best Medicine



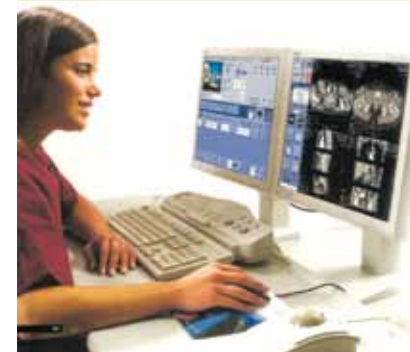"I already diagnosed myself on the Internet. I'm only here for a second opinion."

"It's a new procedure. We can surgically implant tiny detour signs so food won't go to your thighs."

Front Piece

## The seed was sown

Prof. Dr. P.V.A. Mohandas



A few months ago, on my visit to Stuttgart I had visited the Department of Imaging Sciences, Katharinen Hospital. I saw a Radiologist sitting in front of a big screen, looking at the blood supply to the brain. She told me that the patient had come in with a left sided stroke in progress. They had taken a CT Angiogram of the cerebral vessels to study the possibility of any obstruction to the blood flow. She showed me the obstruction to the cerebral artery and invited me to see how she was going to do the stenting. She put in a stent to overcome the obstruction and re-establish blood flow, thereby preventing the patient from getting a stroke. I could really never get this picture out of my mind. I was determined to set up a Centre of Interventional Radiology at MIOT to prevent strokes.

Now we have a full-fledged Department of Interventional Radiology, which can intervene in any part of the human anatomy.

## And the Diagnosis is...

*From the 'no touch' technique of diagnosis to the latest imaging equipment that helps do away with surgery*

In the years gone by doctors could diagnose diseases by looking at a patient. It is said that Dr.Guruswamy, a famous physician did his pooja at 5 a.m., then came and sat on a carpet in his living room and patients presented themselves. He would look at them and make a diagnosis.

This was the "no touch technique".

Then came the era when physicians would feel the pulse and make a diagnosis. Then the world discovered stethoscopes - the proud ornament of doctors, sported around their necks. But this too has become historical.

### The Marvel of Imaging Sciences

Science has developed so much that we make use of Ultrasound, Spiral CT, Scan and Magnetic Resonance Imaging, to delineate various lesions in the human body. With the increase in the incidence of cancer and the availability of various modalities of treatment, tissue diagnosis of various lesions has become necessary. This helps the clinician to plan his strategy to fight the disease – be it chemotherapy, radiotherapy or surgical removal of the lesion.

Removing a part of the tissue and examining it under a microscope is called Biopsy.

Many a time these tumours are in inaccessible sites necessitating major intervention for removal of tissues for diagnosis. Today with improvement in imaging devices,

we can do a biopsy using Ultrasound, CT guided, MRI guided biopsies. We can remove tissue from the brain, thyroid, lungs, heart, stomach, bladder, spinal cord, spine, prostrate etc without having to do a major surgery - it can be done with a needle.

### Image Guided Drainage Procedures

The imaging devices also help in the drainage of collection of pus or fluid from the brain, lungs, abdomen, pelvis, prostrate etc.

### Starving a Tumour

A tumour lives because of the nutrition it receives - it is nourished by the blood vessels. If we can block the blood vessels that supply nourishment to the tumour then the tumour will die. Using image guidance we can, through a blood vessel in the thigh, introduce a catheter, inject a dye and delineate the blood vessels that supply the tumour. Then we block the blood vessels entering the tumour. Thus the tumour is starved of its blood supply and it dies.

Another option is to introduce an umbrella shaped needle into the centre of the tumour. Heat energy is then applied to the mass and the tumour is burnt.

Using Image Guidance, chemical substances like alcohol and other drugs can be injected and the tumour burnt.

Prof. Dr. P.V.A. Mohandas






# Stop that Stroke. Starve that Tumour

Whether it's opening up a clogged artery, stemming blood flow or starving a tumour - Interventional Radiology offers a safe and viable option to open surgery.

Dr. Muralidharan takes us through some revolutionary techniques.



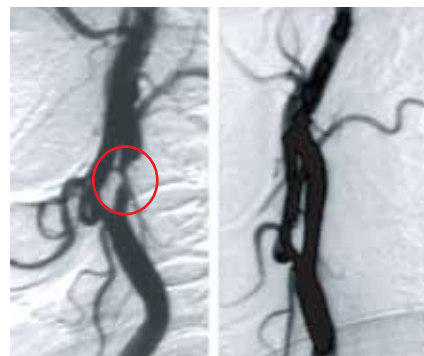Interventional Radiology covers procedures done under imaging guidance (CT Scan, Cath Lab/Ultra Sound) as an alternative to open surgery.

These include **blood vessel blocks:**

A block in the blood vessels in the neck can lead to stroke. Blood vessels in the leg can get blocked due to diabetes/smoking leading to gangrene. A block to the blood vessels in the kidney may result in high BP and renal failure. Previously re-establishing blood flow in these cases involved surgery. Now thanks to Interventional Radiology they can be carried out with local anesthesia.

## Opening Procedures

Here's how: We insert a catheter in



Block in Carotid Artery opened by Angioplasty & Stenting

the groin blood vessel and direct it to the affected area. Using imaging guidance, we then navigate beyond the obstruction and insert a stent to restore blood flow.

## Strokes

It's important to catch the stroke in time. Once the stroke happens it is too late. The warning signs are subtle: sudden stuttering; weakness of hand or leg, which recovers in a few minutes; transient loss of vision.

If any of the symptoms persist the patient must visit the doctor. If we find that there is more than a 70% narrowing of the blood vessel, angioplasty or stenting can be done which is an alternative to open surgery.

## Advantages:

The procedure is done only under local anesthesia.

You can avoid a big incision (and incision related problems).

You will have only a small puncture through the groin.

Shorter hospital stay and quicker recovery.

**Mr. Khader**, a 63 year old man from the Middle East had a stroke years ago from which he had recovered. On and off he continued to suffer from giddiness for which he was on medication. He began to develop transient weakness as well and came to MIOT for investigation.

At MIOT we did a Doppler CT Angio on the patient. It revealed a block to the carotid artery supplying blood to the brain – a narrowing of 80%.

Open surgery was not a consideration as Mr. Khader was high risk patient because of his previous stroke. We explained the new technique of carotid stenting – through which he could avoid open surgery. In this there was a risk of less than 2%.

Then we started the procedure using only local anesthesia. We passed the catheter through the leg put in the balloon and opened it. We used a filter to prevent any clots from travelling to the brain. An overnight stay in the ICU - and 4 days later he was discharged. All his symptoms were gone and a major future stroke was averted.

## Peripheral Arterial Disease in the Legs

**Symptoms:** Pain while walking and eventually while resting too. Small wounds which won't heal leading to gangrene (either for diabetics/smokers /or those with high cholesterol levels).

If you have these symptoms - you can avoid open surgery with stenting. You can avoid amputation through regular check ups with your diabetologist.

## Blocked Blood Vessels in the Kidney

When blood vessels are blocked in the kidney it leads to uncontrolled hypertension. If this is not treated the kidney will lose its function. This too should be treated in time before the kidney starts shrinking.

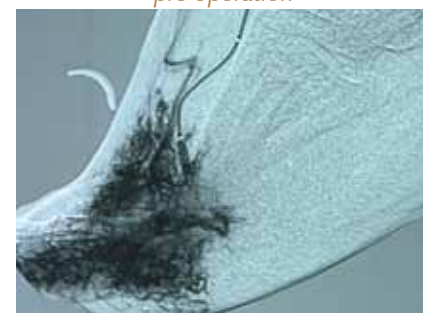## Closing Procedures: Embolisation

Embolisation is a technique that is used for acute life threatening conditions - like coughing up blood or uncontrolled bleeding – in motions, through delivery etc.

The conventional treatment is blood transfusions. First identifying the site of the bleeding, getting to the blood vessel and blocking it with agents – this is embolisation. The rule is - first control the bleeding then diagnose the cause.

## Pre-surgical Treatment of Tumours

A tumour is well supplied with blood. During surgery, when a surgeon tries to remove a tumour there will be a lot of blood loss. So much so that the surgeon will even find it difficult to see the field clearly. A blood transfusion may be required.



Peripheral AVM treated by embolisation

Now, through Interventional Radiology, 2-3 days before surgery, we go in and block the blood vessels supplying the tumour. The result - a bloodless field for the surgeon. Instead of 15 bottles of blood only 4 bottles (less transfusion) may be required. The tumour removal too will be complete and easier.

Some liver tumours cannot be operated on either because of their inoperable location or large size. For these we inject anticancer drugs directly into the tumour through the blood vessels supplying it. This causes the tumour to start shrinking and then it can be removed easily.

## Hysterectomy for Fibroids

For fibroids, hysterectomy has so far proven to be the recommended course. Hysterectomy, as we all know, has its own physiological and psychological effects. Now interventional radiology offers an option. The embolising agents are injected into the uterine blood vessels - so that the fibroid shrinks over time.

As the fibroid shrinks symptoms like: increased bleeding, increased urination, lower abdominal pain, etc. are reduced.

## Advantages:

You save the uterus

No need for surgery

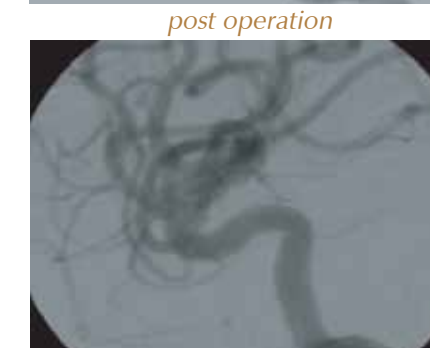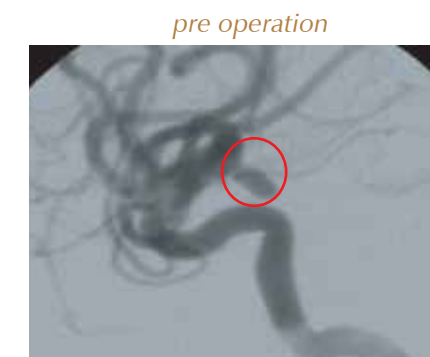Need to be in the hospital for only 2-3 days

## Bleeding in the Brain

Sometimes a blood vessel in the brain bulges (aneurysm) and ruptures – causing very a severe headache. This headache is abnormally intense unlike anything the person has ever experienced before.

During the conventional open treatment, sometimes the patient can become comatose.

We can now treat brain aneurysms



without open surgery through coil improvisation - that is we inject platinum coils which prevent blood from flowing through the aneurysm. This should be done quickly before re-rupture happens which is fatal.

## Brain AVM (Arterio Venous Malfunction)

The symptoms are bleeding, fits or a stroke. This condition is treated through radiation, open therapy, embolisation or a combination of both. All brain and cardio procedures require anesthesia.

## Vertebroplasty

Because of osteoporosis bones become weak and collapse in the vertebra - the height of the vertebra gets reduced resulting in severe pain.

Through imaging guidance we inject bone cement. It kills nerve endings reducing pain. Using X-ray units we inject only the affected vertebra.

The advantages are - no open surgery is required, only a simple puncture. The recovery is complete and dramatic.

**Dr.K.Murali M.D, P.D.C.C.,**  
Consultant & Interventional Radiologist.





# Medicine goes Nuclear

*Don't be alarmed! Nuclear medicine breaks new grounds in helping physicians study the functioning of your organs - says Dr. Venkatachalapathy*

Whether it's chest pain or cancer Nuclear medicine plays a very important role in the early diagnosis of the disease.

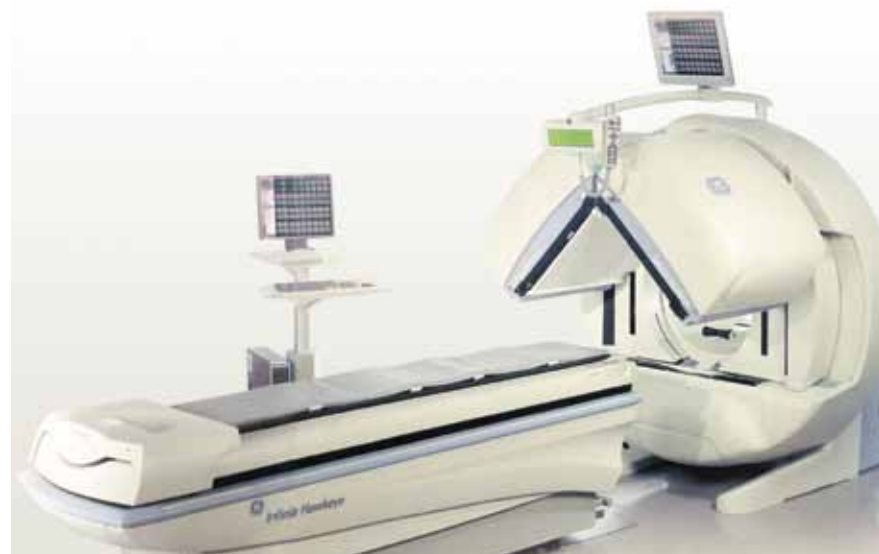Nuclear Medicine is a branch of medicine in which radioactive isotopes are used to treat various diseases.

Usually it takes several days/weeks/months to trace the structural damages that an organ undergoes due to disease. With nuclear scans however, it is easier to discover the functional problems of an organ early and begin appropriate treatment.

## How a nuclear scan is done

A small quantity of radio isotope is administered either through an intravenous injection or orally. By scanning the appropriate organ under a gamma camera we can assess the functioning of an organ.

MIOT has invested in the latest dual head gamma camera from GE.



3-day old baby, safely. There is no age limit for undergoing nuclear scans.

However pregnancy is the only absolute contraindication to undergo any nuclear procedure (scan/therapy).

## What are the common Nuclear Scans?

The commonly done nuclear scans are:

**Thyroid scan:** To see how the thyroid gland functions

**Whole body bone scan:** To see infection/ spread of cancer in the bone

**Renal scan:** To check the functioning of each kidney

**Thallium Heart Scan:** To assess the risk of a heart attack/To know the amount of damaged heart muscle in the event of a heart attack etc.

**Gastro Intestinal Bleed Detection Scan:** To know from where the bleeding comes from

**Meckle's Diverticulum Scan:** To see the presence of Meckle's Diverticulum in children

**Brain Perfusion Scan:** To assess blood supply to brain

**Para Thyroid Scan:** To detect overfunctioning parathyroid gland (It is a whole body scan).

**Radio Iodine Whole Body Scan:** To assess the recurrence of cancer of the thyroid and its spread.

## Various other scans like PET scans

## What are the common Nuclear medicine treatment procedures available?

1. Radio Iodine Therapy for overfunctioning thyroid gland
2. Radio Iodine Therapy for cancer of thyroid
3. Strontium therapy for bone pain due to spread of cancer to the bone

## How I should get my Nuclear Scan done?

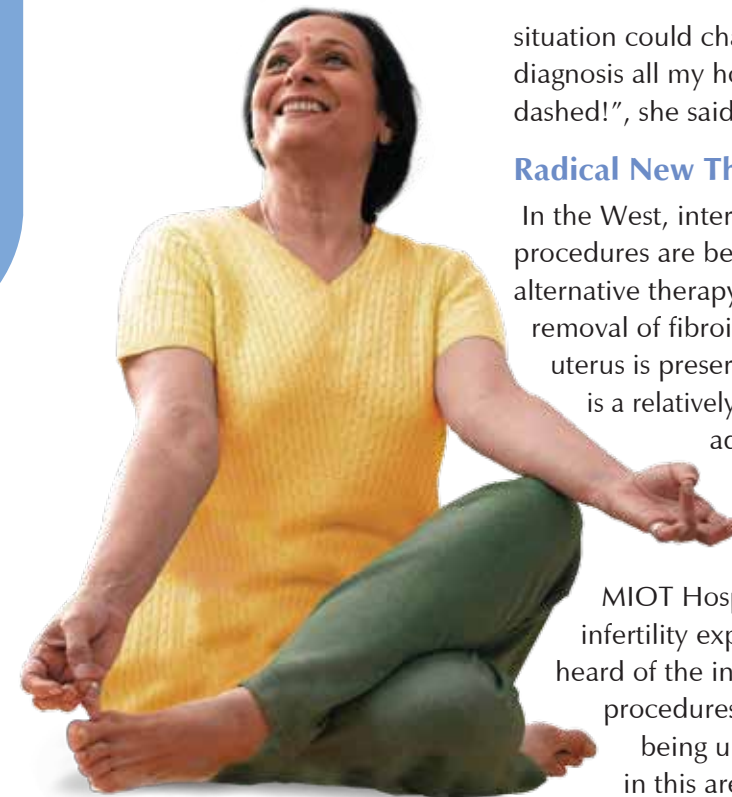
Nuclear medicine procedures whether scan or therapy are always done with prior appointment. There are several guidelines to be followed. Please call ahead and follow strictly the instructions given to patients.

**Dr. E.Venkatachalapathy**  
MBBS DRM DNB (Nuclear Medicine)  
Consultant Nuclear Medicine



# "From No Hope to Hope"

*Does fibroid removal always mean an hysterectomy? Not any more.*



situation could change. With this diagnosis all my hopes were dashed!", she said.

## Radical New Therapy

In the West, interventional procedures are being taken up as alternative therapy for the removal of fibroids whereby the uterus is preserved. In India it is a relatively new procedure, adopted by select hospitals only.

Mrs. Menon was referred to MIOT Hospitals by an infertility expert who had heard of the interventional procedures that were being undertaken by us in this area.

Mrs Kamala Menon (38) had been married for 11 yrs. To her great disappointment her marriage had not been blessed with children. What's more - every month she would suffer - her periods would continue for a long time and involve massive bleeding. Investigation revealed that Mrs. Menon had an abnormally large fibroid (11 cms) in size in her uterus. She was also severely anaemic with an HB count of 4.

Under regular circumstances the fibroid would have to be removed surgically and in all likelihood the uterus would be removed too. This information was devastating to the patient.

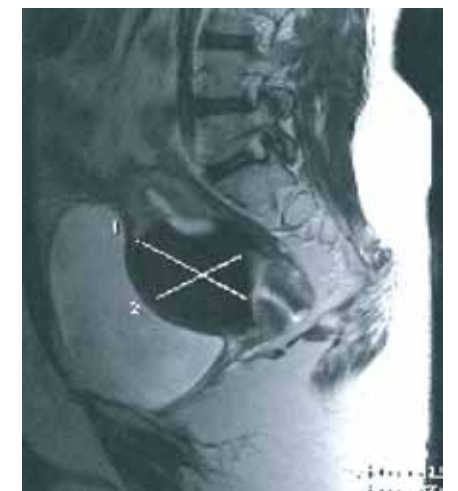
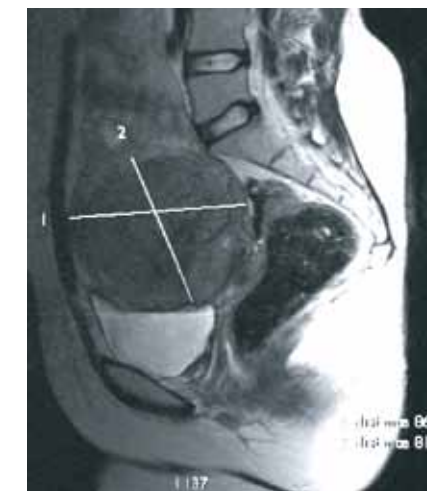"Even though I was childless I always had the hope that the

## How it was done

First we introduced a catheter was introduced into the uterine artery. The flow of blood to the fibroid was blocked with embolising agents. The bleeding was arrested immediately. Starved of blood supply the fibroid would shrink in size gradually over a period of 3-6 months.

After two months we repeated the Ultra Sound, In it the fibroid showed a 30 % reduction in size. Mrs. Menon now has normal periods and her HB counts have improved.

"I thought an hysterectomy was certain!" said a beaming Mrs. Menon. "I am really grateful to MIOT for this effective procedure. All the symptoms and discomforts of the fibroid have almost disappeared, and the best news is that I have a chance to conceive a child!"



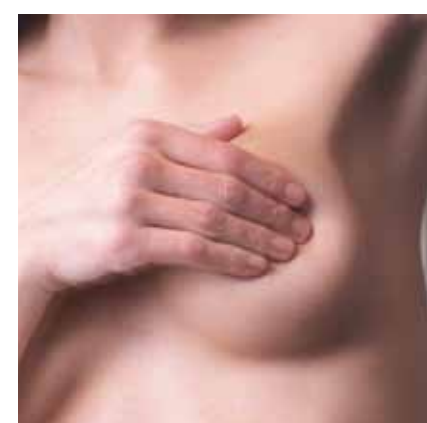Fibroid - 50% reduction in size - 3 month follow up





# The Battle Against Breast Cancer

*The MRI Mammograph plays a vital role in the early detection of breast cancers.*



The incidence of breast cancer is increasing rapidly in India. Breast cancer is one of the most common cancers affecting females. It is estimated that one out of twenty two Indian women is likely to develop breast cancer during her lifetime.

**Risk Factors:**

The mere presence of risk factors does not indicate breast cancer nor can all risk factors for breast cancer

be removed. The following universal suggestions may be made for all Indian women:

- A diet low in fat and rich in vitamins, minerals and antioxidants (through fresh fruits and vegetables)
- Regular exercise and weight control
- Alcohol consumption must be avoided or minimised
- Oral contraceptive pills and Hormone Replacement - treatment must be undertaken under the close supervision of a health care provider
- Self-breast examination must be practiced monthly from teenage onwards by all women
- Clinical breast examination may be undertaken annually with one's doctor

In women who are at higher risk, the doctor may advocate

mammographic surveillance usually from age 35 onwards.

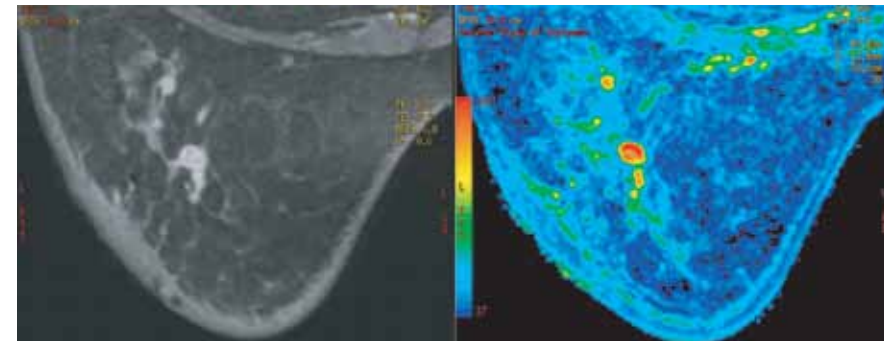
**The Magic of Mammography**

MR Mammogram is a technique of examination of breast using magnetic resonance imaging (MRI). During the study, the patient lies on her stomach with both breasts positioned into a cushioned recess containing the signal receiver (also called the breast coil). The entire bed on which she is lying is then advanced into the opening of the magnet and images are acquired. The study takes around 20 minutes. MRI of breast requires intravenous injection of 'contrast agent' which helps highlight breast abnormalities. The main strength of MRI lies in intricate delineation of soft tissue in the breast and the ability to acquire multiple images of the breast in multiple planes.

The strength of the magnetic field used to perform breast MRI is important because best results are achieved using a high field strength magnet and by using a dedicated breast coil.

The benefits of MRI include:

1. Breast MRI pinpoints the size and location of breast abnormalities and also helps determine the extent of cancer and to detect additional lesions
2. Evaluation of spontaneous nipple discharge
3. Useful after surgery to detect residual cancer
4. Patients with large tumors may have chemotherapy before surgery. Breast MRI is used before and after chemotherapy to see if treatment is working



MR mammogram showing a small cancer in the breast

- and if so, how much the tumor has shrunk.
- 5. Screening of individuals with high risk for developing breast cancer. High-risk individuals include women with strong family history of breast cancer
- To sum up, by looking at the images the radiologist uses breast MRI to answer the following questions:

Is there a breast abnormality or not? If there is an abnormality, does it look like cancer? If it looks like cancer where is it located in the breast, how big is the cancer and how close is it to the chest wall, skin and nipple?

Needless to say the sooner these questions are answered and treatment started the better the chances of halting the disease or saving the breast.

**Dr.R.Madan M.D**  
Consultant Radiologist

## "I can see my baby!"

*These days every pregnant woman undergoes at least two ultrasound scans. What is the ultrasound? What are the advances in ultrasound and what are its applications?*



**Why do we need ultrasound?**

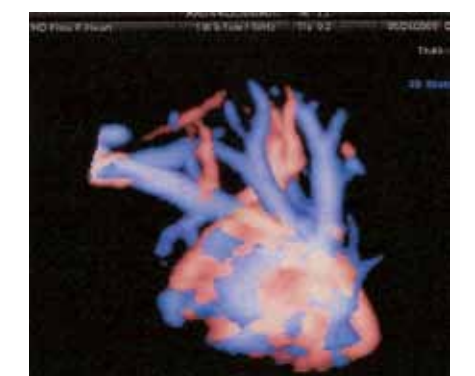
The ultrasound is useful to detect any swelling / masses within the abdominal organs like liver, pancreas, spleen, kidneys, uterus and ovaries. It also helps to detect calculus (stones) in gall bladder and kidney.

The ultrasound is a very preliminary screening and in most cases there might be a need to do a further evaluation with CT or MRI, depending on the problem. These will also help in planning treatment.

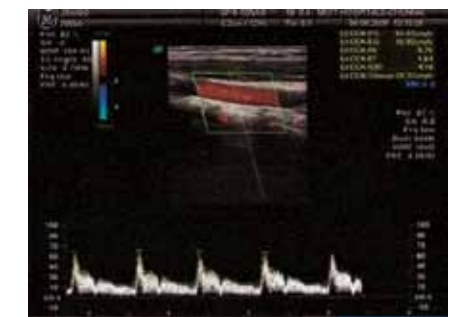
**What is Color Doppler Ultrasound?**

Color Doppler Ultrasound helps us study the blood vessels, which supply the brain, intrabdominal organs and extremities. It indicates any fat deposits that cause the narrowing of the blood vessels. This is helpful in preventing strokes or gangrene of limbs. All diabetic and hypertensive patients are at risk of developing disease of the blood vessels and will

require Doppler examination of the limbs for early diagnosis and treatment.



4D Doppler view of blood in the heart



Color Doppler image of the blood vessel supplying the brain.

Did you know?

Established and probable risk factors of breast cancer	
Factor	High risk group
Age	Elderly women
Gender	1 in 100 cancers affect males
Geographical location	Developed country
Age at onset of first period	Before age 11
Age at natural menopause	After age 54
Age at first full pregnancy	First child in early 40s
Family history	Breast cancer in first degree relative when young
Genetic factors	Presence of some abnormal genes
Past history	Cancer in other breast
Socio-economic group	Higher socio-economic groups
Diet	High intake of saturated fat
Obesity	Body mass index > 35
Alcohol consumption	Excessive intake
Exposure to radiation	Abnormal exposure in young girls after age 10
Oral contraceptives	Current and recent use
Hormone replacement therapy	Current and recent use

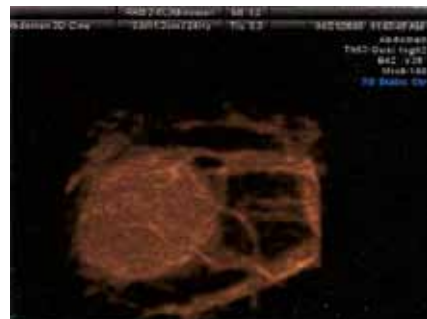




The ultrasound also useful to study if there is any narrowing of blood vessel, supplying the kidneys. Any disease of the blood vessel supplying the kidneys is likely to cause severe uncontrolled hypertension. This is more likely for diabetics.

The Color Doppler also helps to rule out blood clots in the blood vessels, which if dislodged may travel to the lungs and cause a life threatening condition. This can be prevented if the blood clot is found and treated. Vascularity of tumors can be studied which helps in diagnosis as well as pre surgical planning.

The Color Doppler ultrasound can be used to identify the weak blood vessel causing varicose veins which can be marked by ultrasound, helping the surgeon to locate and treat it.



4D view of blood vessel supplying the tumor.

**Then what is 4D ultrasound?**

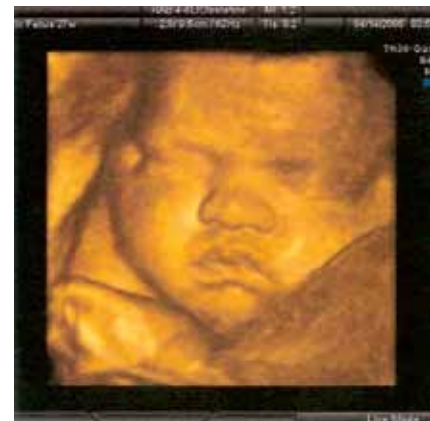Normally a 2D ultrasound is performed. In 4D ultrasound the image formed is a 3 dimensional with live movements.

**What is the role and advantages of 4D ultrasound?**

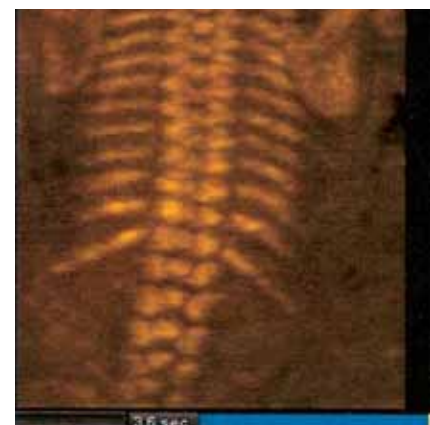At MIOT Hospitals we have the latest and world's best 4D ultrasound scanner which is done mainly for pregnant ladies, though it is being used for 4D vascular imaging of carotid vessels, peripheral vessels and vascularity of organs and tumors as well.

**4D Obstetric ultrasound:**

Every pregnant lady will require at least 3 ultrasound examinations during the pregnancy. 4D ultrasounds give a true 3 dimensional image of the fetus is seen in true



3D view of baby's face



3D view of baby's spine

motion. This helps parents to visualize the unborn fetus and helps the examining physician to identify structural anomalies and growth.

In early pregnancy ultrasound confirms the pregnancy and tells us whether the fetus is within the uterus or outside the uterus. In the 2nd trimester the growth of the fetus can be evaluated and individual parts of the fetus can be studied in detail to rule out structural abnormality. In late pregnancy any distress to the fetus can be identified early by Doppler ultrasound of fetal brain and umbilical blood vessels.

**Ultrasound guided aspiration and biopsies**

With the help of ultrasound, fluid collection in any part of the body can be localized and a needle inserted into the fluid collection and drained without the need to undergo open surgery. The same procedure is followed for biopsy of tumors in lungs, kidneys, breast and prostate. 4D scanning gives a true volume image by which accurate localizing and biopsy of breast and prostate tumors can be done.

**Dr.G.Francis DMRD, DNB.**  
Consultant Radiologist

Cutting Edge

**Technology For You**

*MIOT's new Digital Cath Lab takes angiography to the next level*

Welcome to the latest in technology – the new Digital Cath Lab. The Digital Cath Lab is used for performing invasive angiography. Angiography is the study of blood vessels in the body. Though there are other modalities where angiography can be done like CT angiography or MR angiography we still need invasive angiography prior to planning interventions or surgery.

**First of its kind**

The Digital Substraction Angiography (DSA) unit in MIOT Hospitals is a flat panel detector (latest in the medical field) Cath Lab with provision for performing angiography on any portion of the body. In addition to the regular 2D images, this unit can perform Rote Horizon Angiography with 3D reconstruction, popularly called as 3D DSA. In fact this unit is the first of its kind on the country with a flat panel cath lab.

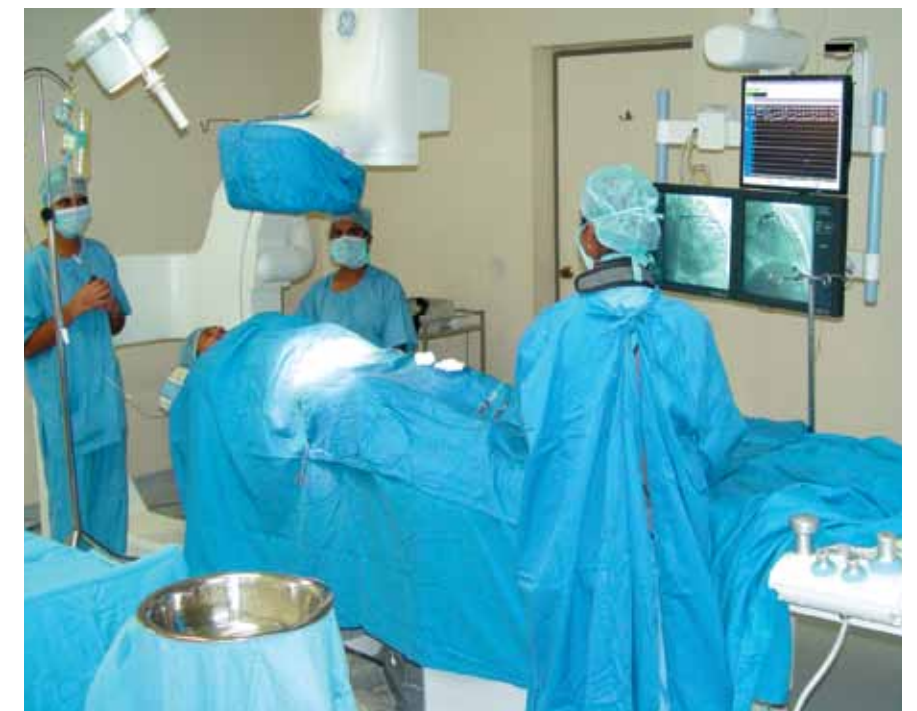3D DSA is popularly used to perform angiogram of the brain, especially for planning of treatment of brain aneuengiama, AUM, etc.

The unit also has a facility of ROAD MAP, using which the radiologist can precisely guide a catheter or device into any where in the body from the groin.

**Clinical Uses:**

**Opening up of blocked blood vessels with angioplasty and stenting**

- a) Carotid and vertebral angioplasty and stenting (opening up of narrowed blood vessels in neck) to prevent stroke



- b) Intracranial angioplasty and stenting (opening up of narrowed brain blood vessels)
- c) Renal angioplasty and stenting (opening up of narrowed blood vessels to kidney)
- d) Angioplasty of lower limb blood vessels

**Closure of abnormal blood vessels (embolisation)**

- a) Brain aneurysm coiling: Coils are placed in a brain aneurysm preventing bleeding
- b) Brain AVM (Arterio Varicose Malfunction) blockage with liquid agents
- c) Pre-operative embolisation: Blocking bleeding blood vessels prior to surgery

**Blocking blood supply to fibroids in uterus as an alternative to open surgery ((depriving them of blood**

**leads to the shrinkage of fibroids)**

- a) Blocking peripheral angiogram/AVM
- b) Delivering anticancer drugs directly to liver tumours through the blood vessels supplying it
- c) Direct injection of embolising agents into venous malfunction
- d) Emergency blocking of excessive bleeding from lungs, in motions during childbirth, etc.

Guidance of catheters, curers and coils into the desired part of the body require a high resolution cath lab. The flat panel DSA unit with rotational 3D angiography aids the interventional radiologist in performing these tasks precisely, reducing the risk of complications.

**Dr.K.Murali M.D, P.D.C.C.,**  
Consultant & Interventional Radiologist.



Are you  
winning  
the losing  
battle



MIOT also launches WOW – War Over Weight. A customized programme and support group for people who are severely overweight. WOW offers individual consultations, medical check up, nutrition counselling, surgical options for weight loss, family counselling and more. Contact us and get a weight off your mind!

*Please call for appointments. Tel 98410 13863*



**MIOT Hospitals** 4/112, Mount Poonamallee Road, Manapakkam, Chennai - 600 089  
Tel: 2249 2288 Fax: 2249 1188 Email: [miot@vsnl.com](mailto:miot@vsnl.com) [www.miothospitals.com](http://www.miothospitals.com)