



MARUTHUVA VIVEKAM

Doctors Advice - For a Healthier Life




Plus:

*A Hairy Cause for
Backache*

Know your Spine

To Hell and Back



BACK TO THE FUTURE

What's behind the common
backache? A look at spinal
ailments and beyond.



From the Chairman's Desk



Dear Friends,

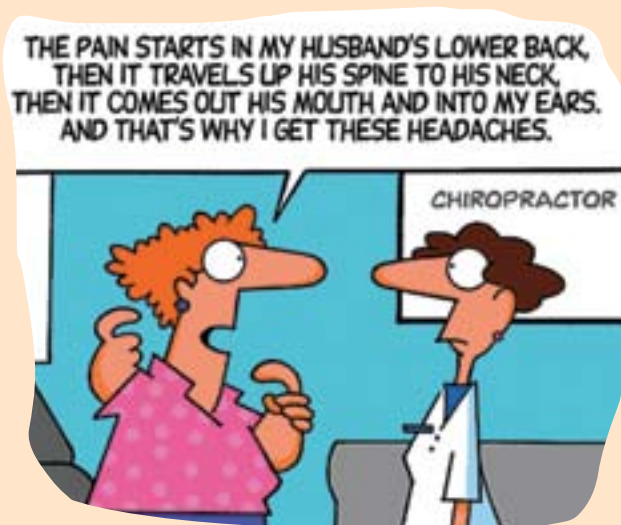Greetings. These days so many of us suffer from backache – it strikes equally, people of both sexes and all ages. Sometimes we can link the pain to an accident or action, sometimes it appears without a cause. The point is, a backache could be a front for a whole lot of ailments from complex spinal disorders to (believe it or not) ingrowing hair! In this issue of Maruthuva Vivekam we take a look at the causes, ailments, diagnosis and treatment of spinal disorders – gathered from our years of experience in dealing with all kinds of spinal surgeries. I hope you will find this issue useful. Do mail me

feedback at enq@miot Hospitals.com.

Here's wishing you all a Happy and Healthy 2009!

Mrs. Mallika Mohandas
Chairman, MIOT Hospitals

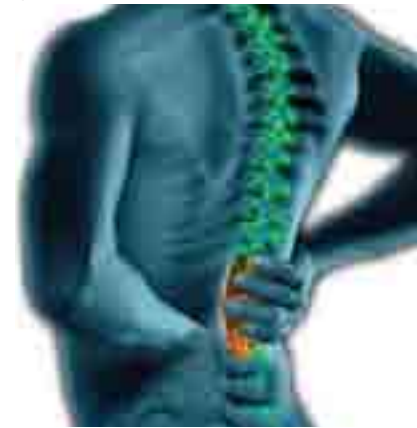Laughter is the Best Medicine



Front Piece

OH ! MY ACHING BACK

Pain in the back is a very common complaint in any age group! We often attribute this pain to a problem with the back muscles, or a ligament sprain or blame the back bone or the disc. Often we are treated with home remedies and grandmother's concoctions and if the pain persists for days, then we go to the doctor.



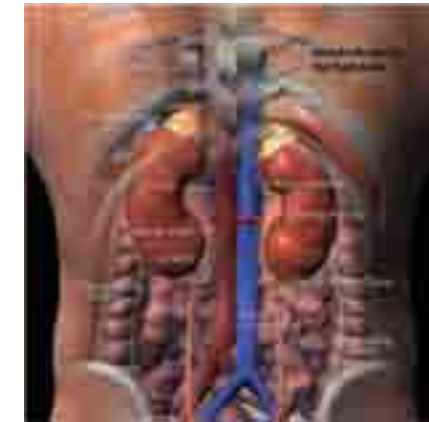Behind back pain

At the outset I must enlighten you that back pain can be either due to the back or due to problems in the organs which lie close to the back. Back pain may also be due to problems in the lungs in the pleura (tissue covering the lungs) in the heart or covering the heart (pericardium), windpipe or the food pipe. The back pain may be due to diseases in the abdomen, ulcers in the stomach, duodenum, pancreas, intestines, uterus, ovaries, bladder and the prostate in men.

Any disease in these organs can present itself as back pain.

So doctors classify back pain as:

1. Spondylogenic – due to problems in the vertebrae or ligaments and



muscles attached to the vertebra.

2. Discogenic due to problems with the disc.

3. Viscerogenic diseases connected with organs that lie close to the vertebral column.

4. Vascular back ache due to diseases of the blood vessels, like aneurysms of the abdominal aorta.

5. Neurogenic - conditions affecting the nerves or spinal cord.

6. Psychogenic - problems connected with the mind.

Some common causes

Each one of the problems stated above may be due to the following conditions:

- Congenital defect in the bone or various organs
- Developmental disorders
- Metabolic problems
- Nutritional problems
- Infections like Tuberculosis or pyogenic infections
- Parasitic infections like hydatid cysts, cysticercosis, brucellosis
- Hormonal changes
- Osteoporosis
- Tumours – benign or malignant
- Spinal injuries or abdominal viscera
- Degeneration (wear and tear)

So if you have a backache that persists you have to seek the opinion of a knowledgeable doctor who can put his finger on the particular cause of the pain.

Is surgery required?

In young people, it is often the disc (slipped disc) which causes a problem and this can give an annoying ache in the back, throughout life. When I was a Professor at the Medical College, I graded disc lesions depending upon the severity, so that doctors will have a guide as to what treatment they should advise the patient.

Grade I – rupture of the outer covering of the disc

Grade II – bulge without causing pressure on the nerves behind

Grade III – bulging of disc with pressure on the nerve roots causing numbness or weakness of the muscles

Grade IV – bladder paralysis

Grade V – chronic disc with instability of the vertebrae itself

I advocated treating Grade I and Grade II with rest, painkillers, massage, lumbo sacral belt etc. Grade III, I advocated surgery. Grade IV I treated as an emergency requiring immediate and urgent surgery. Grade V requires surgery – decompression and stabilization of the vertebrae.

I am glad that we have dedicated this Maruthuva Vivekam to spinal disorders and I hope readers will benefit from this volume.

Prof. Dr. P.V.A. Mohandas

Know your Spine

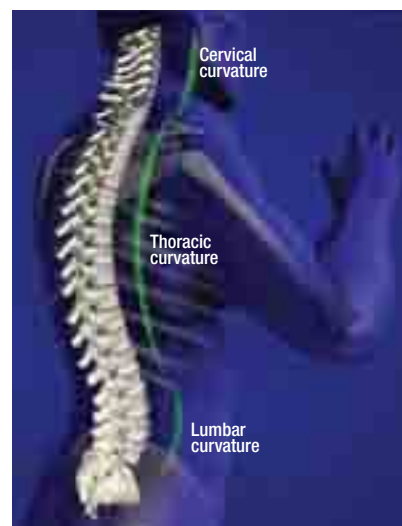
To understand spinal injury, ailments and treatment, we must first understand our spine...

The spine is one of the most important structures in the human body, supporting much of your weight and protecting the spinal cord, the delicate nervous tissue which carries communication from the brain to the rest of the body. The spine is a strong but flexible column, allowing a wide range of movement.

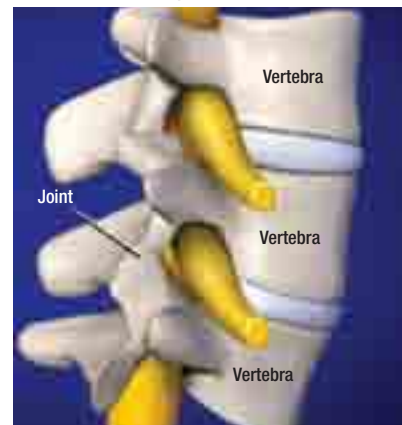
All about vertebrae

The spine extends from the base of the skull to the tailbone and is made up of thirty-three bones known as the vertebrae. The first seven vertebrae (cervical vertebrae) are in the neck and are numbered 'C'1 through 'C'7. Nerve compression in this area can cause neck pain, which may radiate down the arms to the hands and fingers. The next twelve vertebrae make up the thoracic region ('T'1 through 'T'12); the ribs attach to these vertebrae and protect the heart and lungs.

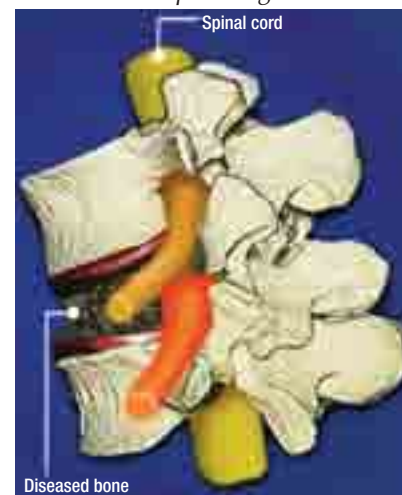The lumbar region is the lower back, which contains five vertebrae ('L'1 through 'L'5). It plays a significant role in motion and flexibility. It is the source of most motion and supports most of the body weight. Overload or taxing movements may strain the structure, compress the nerves and cause back pain, which may radiate down the legs to the feet.



Normal spinal curvatures



Stable spinal segment



Unstable spine due to vertebral body destruction

The regions beneath the lumbar spine are the sacrum ('S'1 through 'S'5) and coccyx (a series of small bones often called the tailbone). These are fused; they do not have discs between them.

Discs – shock absorbers of the spine

The vertebrae in the cervical, thoracic and lumbar regions are separated by discs. A disc serves as a cushion and allows motion between the vertebrae.

Thus an articulated spine is a column of individual vertebrae neatly piled like a stalk of coins held together by discs and ligament, protecting and allowing optimum function of spinal cord and nerve roots. If the vertebrae, disc or ligaments of the spine are damaged it renders the spine unstable and jeopardizes the function of the spinal cord and can cause paralysis and bladder and bowel incontinence.

Spinal instability

Instability of the spine is the inability of spinal column to sustain physiological loads without endangering the function of the spinal cord or nerve roots. There are a number of factors that can cause instability in spine.

Trauma

Trauma is the commonest cause of acute spinal instability due to injury

Lead Article

to bone, disc and ligaments supporting the spine, risking spinal cord function (primary cord injury occurring at the time of trauma). If unrecognized or untreated, manipulation of unstable spine, can further damage the spinal cord (secondary cord injury) and a patient previously normal can be paralyzed later on. Prompt stabilization of the injured spine is essential not only to prevent secondary cord injury but also to provide an optimal stable environment for the primary cord damage to recover.

Tuberculosis

Though Tuberculosis is a medical disease, when it affects the spine it can cause enough destruction of vertebral body to render the spine unstable. Further pus and unhealthy tissue from infection may cause an abscess compressing the spinal cord and necessitating surgery.

Tumour

A bone affected by tumour is like a wooden log infested by white ants. Just as white ants infest and destroy wood in no time, similarly spinal tumors can cause enough

destruction to cause instability and pathological fracture. Tumor mass itself may compress the spinal cord and cause paralysis necessitating surgery.

Disc degeneration

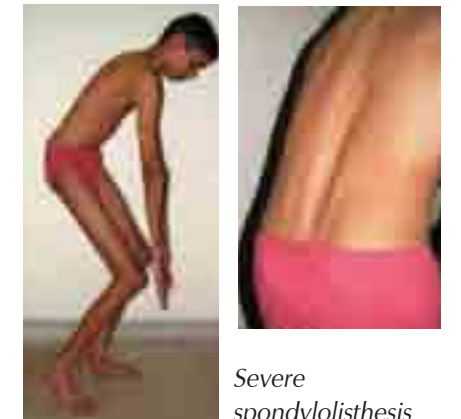With age, discs between the vertebrae can dry out and can no longer cushion and absorb shock in the spine. Rapid degeneration may lead to instability.

Iatrogenic instability

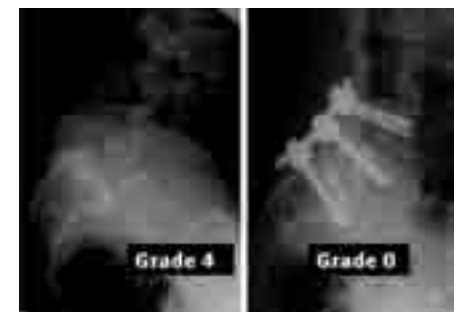Over-enthusiastic spinal decompression can lead to damage to the facet joints (posterior joints in spine) leading to instability. Multiple level laminectomies can also lead to instability.

Spondylolisthesis

Congenital or acquired weakness in the pars (hook mechanism of the spine which prevents forward slip of vertebrae) causes shearing stresses at the disc which undergoes premature degeneration causing instability. Strong implants are required not only to neutralize the shearing stresses but also to reduce the slip and ensure sound fusion.



Severe spondylolisthesis causing hamstrings spasm and spine step-off.

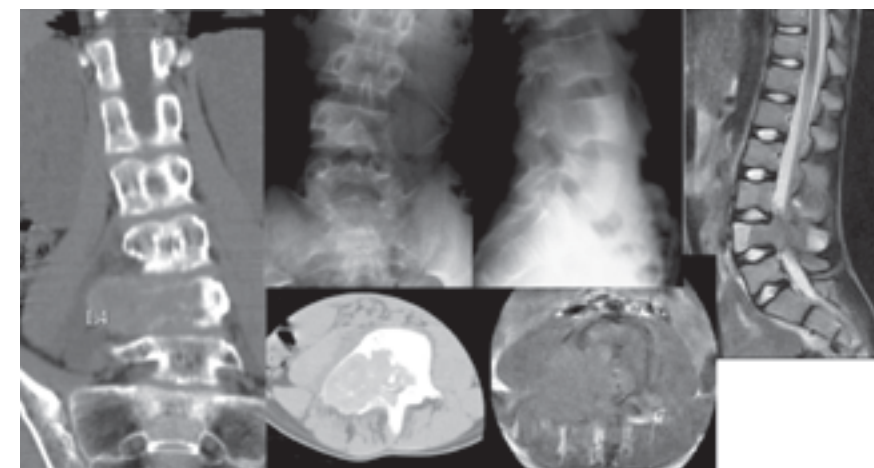


Spinal deformity

Spinal implants are required not only to correct spinal deformities but also to maintain correction till solid spinal fusion occurs.



Correction of scoliosis by pedicle screws and hooks



L4 aneurysmal bone cyst causing cauda-equina syndrome due to epidural compression. Spinal stabilization is necessary to prevent pathological fracture as well as instability resulting from tumor excision.

Dr.C.S.Dhillon
Director, MIOT Centre for Spine Surgery



Spine Surgeries Get Minimal

Keyhole techniques applied to complex spinal surgery reduce pain, scarring, bleeding and recovery time.

In the past decade Spine surgery has witnessed exponential growth in techniques and technologies. Numerous patients have benefited from this. Growing experience and feedback from follow-ups after conventional spine surgeries, brought surgeons face to face with the shortcomings of these open surgeries. Patients too were dissatisfied with some of the untoward effects.

Enter Keyhole Surgery of the Spine

Conventional spinal surgery involves large incisions, extensive soft tissue dissection, laminectomies etc. This approach leads to :

- Larger blood loss during surgery
- Delayed post-operative recuperation
- Longer hospital stay
- Delayed return to normal life
- Extensive scarring

All these, have given rise to a large group of patients termed as "FAILED BACKS". Not only do these failed back patients cast a shadow on spinal surgeries but it is not easy to revise these surgeries and produce better outcomes.

In addition to this, in today's competitive scenario a patient demands treatment that puts him back on his feet as soon as possible.

This forced spinal surgeons to explore a friendlier and less invasive surgical technique called "Minimally Invasive Spine Surgery" or what we

at MIOT call "Keyhole Surgery".

Concept of Keyhole Spine Surgery:

- Aims to preserve as much normal tissue as possible
- Least possible damage to normal physiology
- Improves and speeds up post-operative rehabilitation
- Reduces the untoward effects of conventional open surgeries like fibrosis and scarring

In a nutshell, Keyhole Surgery of the Spine aims to help a patient to get back to his normal active life with the least possible surgical intervention.

Minimally Invasive Disc Surgeries:

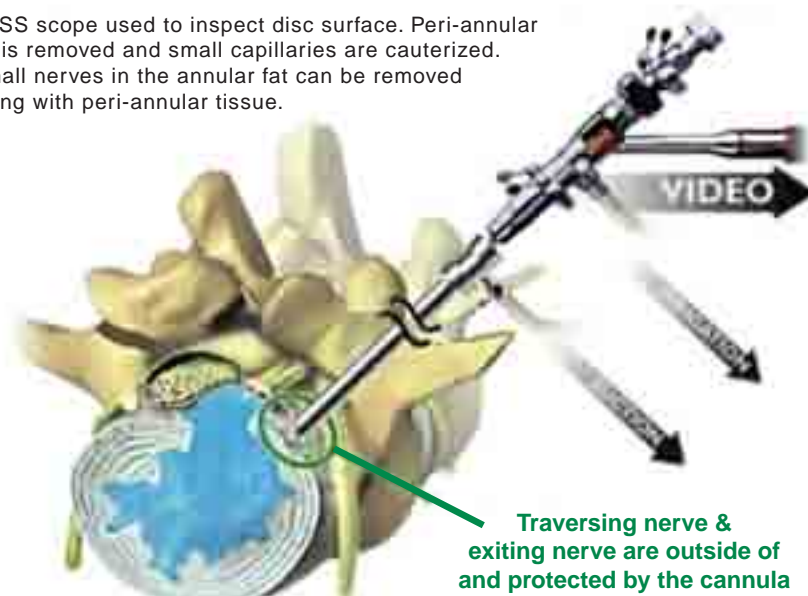
For many years spinal procedures like laminectomy and discectomy have been replaced by

microdiscectomy for lumbar disc herniations. However, even microdiscectomy requires dissection around nerves, coagulation to control bleeding, nerve retraction, minimal muscle stripping and ligamentum flavum resection.

To avoid all the above surgical violations of normal tissue, discectomies are now done via an endoscopic approach. PELD (percutaneous endoscopic lumbar discectomy)/ PECD (percutaneous endoscopic cervical discectomies) are done through a posterolateral (from the back) transforaminal approach for lumbar spine and anterior approach (from the front) for cervical spine. They are done under local anesthesia avoiding the risks associated with general anesthesia. During the procedure muscles are

Selection Endoscopic Discectomy (SED)

YESS scope used to inspect disc surface. Peri-annular fat is removed and small capillaries are cauterized. Small nerves in the annular fat can be removed along with peri-annular tissue.



Cutting Edge

dilated upto just 8mm. There is negligible surgical violation of the epidural space around the spinal nerves. The patient can walk out of the operating room and can be discharged on the same day.

Gold Standard Surgical Technique

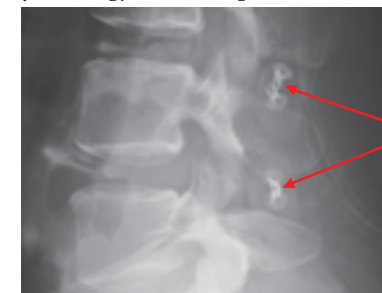Fusion surgeries have been the gold standard surgical technique for the unstable spine and for multiple degenerated disc disease.

Fusion has its own disadvantages like extensive surgical dissection, blood loss, possibility of non-fusion and adjacent segment disease. To avoid these complications, Keyhole surgery of the spine is done either by using a total cervical/lumbar disc replacement or by using the posterior interspinous stabilizing devices.

Interspinous devices that basically work by restoring the posterior tension band of a motion-segment, have already been successful in degenerated motion-segment. There are a number of interspinous devices available like X-Stop, DIAM, Coflex, Wallis etc.

DIAM (Device for Intervertebral Assisted Motion):

DIAM is an implantable device for non-fusion surgeries of spinal pathology. It is designed so that



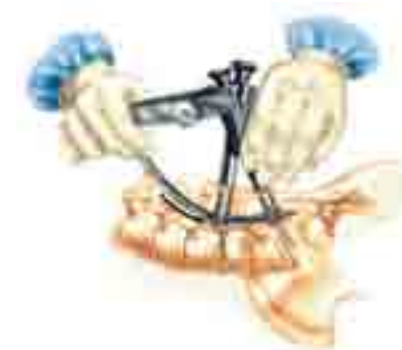patients with spinal pathologies can be treated with minimal invasiveness.

The device is implanted in between two spinous processes in the lumbar spine.

DIAM is used to stabilize the spine that has been destabilized by age-related degenerative process. DIAM stabilization is generally coupled with disc surgeries or surgeries for lumbar canal narrowing. The prerequisite of DIAM stabilization is minimally invasive microdecompression of diseased segment.

Microdecompression preserves most of the normal bone and only removes the offending diseased portion of the tissue. It does not require very large skin incision, nor does it require extensive soft tissue dissection. As a result there is little postoperative scarring, less blood loss, less postoperative pain and very rapid rehabilitation. Patients walk a few hours after surgery.

Minimally Invasive Fusion Surgeries:



There are multiple pathologies of the spine that can only be treated by rigid stabilization and fusion like spinal trauma, lytic or dysplastic lysis, infection, tumor, etc..

In minimally invasive fusion surgeries, the spine is approached with a muscle friendly approach. Instead of doing a wide decompression, microdecompression is attempted to

preserve the natural barrier. Instead of a large incision for pedicle screw insertion, the screws are placed percutaneously from separate stab incisions. Screws are connected with a rod that is also inserted percutaneously from separate stab incisions. This technique not only preserves a healthy muscle cover but also reduces the blood loss during surgery helping patients recover faster.

Minimally Invasive Surgery for Fractures of Spine:

Most spinal fractures require decompression and stabilization by anterior and/or posterior approach.



Smaller incisions leave smaller scars in minimally invasive surgery of the spine.

Cutting Edge



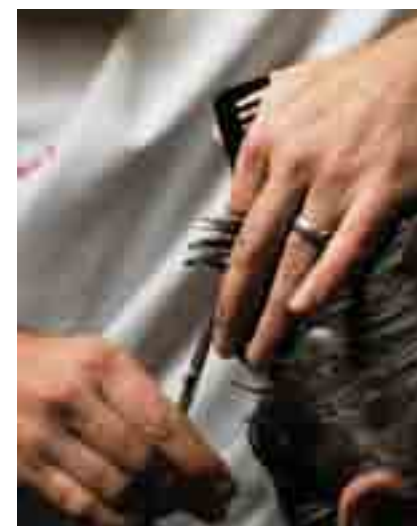A Hairy Cause for Backache

Low backache many a times is caused by a myriad of reasons one of which is a hairy one - namely the 'pilonidal sinus.'

'Pilo' in Latin means hair and 'nidal' is nest, in other words, a nest of hair. These are deep infections situated usually in the natal cleft of young adults. They are formed by the tip of hair follicles inverting and stabbing the skin like a sword, due to the suction effect of the deep natal cleft in individuals with hairy bottoms, who sit for long periods of time. Hence in World War II, it was known as "Jeep Bottom Disease" or "Jeep Driver Disease".

Embarassing situation

This condition could also be congenital - where the hair follicles do not surface at all and are located below the skin. Barbers are also prone to it as an occupational hazard. For them, the hair gets



trapped in the webbing of their fingers as they cut off the wet ends from their customer's hair. These razor sharp ends get embedded in the barber's hand.

Embarassed by its location, patients hesitate to consult a doctor immediately and this neglect often results in abscess and chronic sinus formation leading to other complex problems with pain and multiple sinus tracts, at times extending deep to the bone.

Permanent relief

In this situation, merely removing the pus will fail to cure the problem and may only give temporary relief. For a permanent cure, a proper study into the layout of the sinus tract should be done, through an MRI, followed by total removal and covering up

with a surrounding rhomboid skin flap - which will not only resolve the problem but also flatten the natal cleft and reduce the hair growth over the scar tissue.

So the next time you have a backache look twice and consult a doctor to avoid a hairy problem.

Dr. Rajesh Daniel,
Consultant General Surgeon

Starve that tumour!

Pre-operative embolisation of spinal tumours can prevent excessive bleeding and the need for transfusions

Usually tumours involving the backbone or spine press the spinal cord causing loss of power in legs or hands. These are usually treated by surgical removal. Some of these tumours have an extensive blood supply which can cause torrential bleeding during surgery. This profuse bleeding may hinder complete removal of the tumour and can even be life threatening, by reducing the circulating blood volume.

Is there way out?

Today we have a technique to reduce the blood supply to a tumor 24 - 48 hours prior to tumour surgery.

This is done by making a pinhole incision in the groin and taking a small catheter into the abnormal blood vessels. These vessels are blocked and tumoural blood supply is completely arrested by the injection of special agents. This procedure is called embolisation.

Pinhole to the rescue

Since the tumour is starved of blood supply, the surgical field is very clear. The bleeding is minimal and the patient will not require a blood transfusion.

Who performs the procedure?



The Interventional Radiologist does this procedure in a digital cathlab. Take the case of Mrs. Fernandez. This 35 year old woman had been devastated by the news that she had a spinal tumour. This tumour caused a compression of her spinal cord and resulted in paralysis of her legs. She was now scheduled for

surgery for tumour removal. 48 hours prior to surgery Mrs Fernandez was injected with polyvinyl alcohol particles. This embolisation began starving the tumour of blood.

She subsequently underwent successful surgical removal of her tumour with spinal stabilization. She has recovered completely and today she is walking without any support.

Dr.K. Murali, Interventional Radiologist

Using percutaneous screws, posterior stabilization can be achieved through a stab incision without any damage to soft tissue or without significant blood loss.

Advantages of Keyhole Spine Surgery:

- Less tissue trauma
- Less blood loss
- Preservation of physiologically important normal structures
- Rapid postoperative recuperation
- Decreased hospital stay
- Early return to normal functional status
- Decreased incidence of failed back surgeries
- Increased patient satisfaction

This is just the beginning

Minimally invasive spinal surgery is in its infancy. With further advances in optics and surgical technologies more and more spinal pathologies will be treated with the keyhole concept increasing patients' satisfaction and the success rate of spinal surgeries.

Dr. Niraj Bhupendra Vasavada,
Consultant Spine Surgeon



To Hell and Back!

18

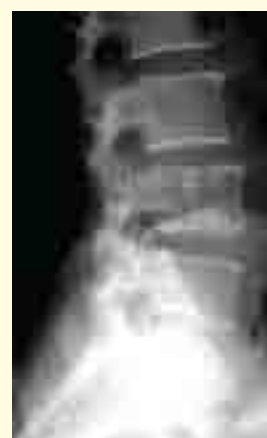Mr. Sharma, a 40 year old executive had been having backache off and on for almost two months. He attributed it to bad posture and ignored his back. His pain did not wane. Instead, it kept on increasing – it was continuous throughout the day and intensified at nights.

“Probably lumbago”, thought his family doctor. He recommended a week of bed rest. A week later Mr. Sharma found that far from subsiding, the pain actually worsened. He was unable to sit or stand comfortably.

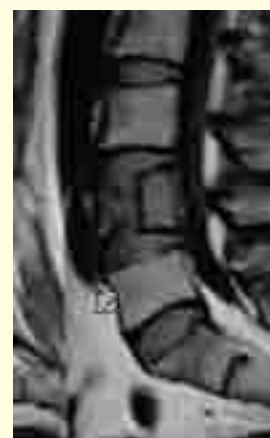The next step

He decided to see a specialist. As he narrated his symptoms to the surgeon in the Out Patients Department, he could see the concern on the doctor’s face. He was advised to undergo X-rays. ‘But my family doctor said that the spinal discs cannot be viewed on X-rays’, argued Mr. Sharma. “It is not the disc I am concerned about... it ‘s something more serious”- confided the surgeon.

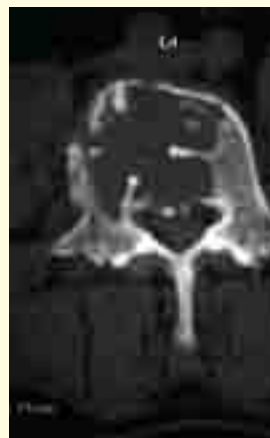When the X-rays were taken, the surgeon had bad news. “You have a tumour in your back”, he told Mr. Sharma, “and you need to be admitted immediately”.



Xrays of Mr. S showing destruction of the L4 vertebra by tumour



MRI showing the extent of the tumour



CT Scan showing how the L4 vertebra has been eaten away by the tumour

The beginning of the end?

“What?” exclaimed Mr. Sharma, “I don’t smoke... I don’t drink... And I am only 40. How can that be?” The surgeon calmed him down. “Bone tumours are

19

not caused by smoking or drinking. Nor is any age immune to malignancy”. He showed him how his entire vertebrae was eaten away by the tumour.

“Is this the beginning of my end?” Mr. Sharma was depressed. “No” said the surgeon. “Not all tumours of the spine are malignant (growing relentlessly leading to death). We need a biopsy to find out what type of tumour this is”.

Swift and Painless

Full of fears, Mr. Sharma was relieved to find that the biopsy was a small procedure not requiring anesthesia. In MIOT, using advanced technology a bit of vertebral body could be removed for biopsy through a transpedicular route without even making a skin incision. Mr. Sharma could walk in an hour.

Fortunately for him the tumour turned out to have not so potent a growth potential. And one that could be destroyed by radiation. Mr. Sharma underwent the prescribed radiotherapy with successful outcome.

Back to the future

Mr. Sharma has resumed his office duties with renewed vigor. He is absolutely pain free. He enjoys a game of tennis every weekend and does not abstain from heavy physical activities. He leads a normal life. But he does not forget to report to MIOT every 6 months for a routine check-up.

Truly not all backaches are due to degenerated discs. Many of these are due to other conditions like sub clinical trauma, infection, tumours or pain from abdomen which needs to be treated aggressively. Backache can also be due to tumours if:-

- The pain appears unrelated to activities like sitting, standing.
- Backaches persist after adequate bed rest.
- Night pains preventing sleep.
- History of previous tumour treatment.
- Recent weight loss.
- Reduced appetite, feeling weak.
- Age above 60.



Oh No! Its Osteoporosis

Thanks to modern medicine life expectancy is on the increase. But one can enjoy the 'golden years' only if one is disability free. One of the biggest causes of disability, fractures, aches and pains in the old age is OSTEOPOROSIS.



Osteoporosis has been defined as a Metabolic Disease characterised by low bone mass and deterioration of bony tissue leading to fragile bones and an enhanced risk of fractures.

Beginning with the bone

Bone is a living growing tissue. It is made up mostly of collagen, a protein that provides the soft framework and calcium phosphate, a mineral that adds strength and hardness to the framework. More than 99% of the body's calcium is contained in the bones and teeth. The remaining 1% is found in the blood.

Throughout one's lifetime, old bone is removed (resorption) and new bone is added to the skeleton

(formation). During childhood and teenage years, new bone is added faster than the old bone is removed. As a result bones become larger, heavier and denser. Bone formation continues at a pace faster than resorption until peak bone mass is reached in the mid 20s. After age 30, bone resorption slowly begins to exceed bone formation. Bone loss is most rapid in the first five years after menopause but persists in the post menopausal years.

Understanding Osteoporosis

Osteoporosis develops when bone resorption occurs too quickly or if the replacement occurs too slowly. Bone loss occurs when the balance between bone removal and

replacement is altered causing less bone to be replaced than was removed. The consequence is reduced bone mass and increase in fracture risk.

Facts and figures

Osteoporosis affects 50% of females and 30% of males above 65 years. It is estimated that 10% of Indian population above 65 years and at least 5 crore people are at risk for Osteoporotic fractures. Out of 6.1 crore Osteoporotic fractures (as in 2005) 50 lakhs will have fracture of the spine or hip every year. One in every third post menopausal women is at risk of fracture.

Risk factors

Risk factors you cannot change-(non modifiable)

1. GENDER

Your chances of developing osteoporosis are greater if you are a woman. Women have less bone tissue and lose it more rapidly than men because of changes involved in menopause.

2. AGE

The older you are the greater the risk of osteoporosis. Your bones become less dense and weaker as one ages.

3. BODY SIZE

Small thin boned women are at greater risk.

Article

4. ETHNICITY

Caucasian and Asian women are at highest risk when compared to Africans and Latinos.

Family History

Susceptibility to fracture may be hereditary. People whose parents have history of fractures also seem to have reduced bone mass and may be at risk for fractures.

Risk factors you can change (modifiable)

1. Sex Hormone Deficiency:

Abnormal absence of periods (Amenorrhea), cessation of periods (menopause) in a female and low testosterone levels in a male.

2. Anorexia

3. Life time diet low in Calcium and Vit-D

4. Use of certain medication such as cortisone and some anticonvulsants

5. Inactive lifestyle and extended bed rest

6. Cigarette smoking

7. Excessive alcohol consumption

Whom to screen

1. Women with strong risk factors

a. Premature menopause < 40 years

b. H/o Ovarian Removal

c. Family history of osteoporosis or atraumatic fractures

d. Short stature, small frame (BMI < 19) and weight < 127 lbs or 58 kgs

e. Whites > Asians > Blacks

2. Osteopenia or Spinal deformity on X-Rays

3. Patient with poor nutrition and lack of exposure to sunlight

4. Patient on long term steroid therapy (Oral Prednisolone > 7.5 mg/day Inhaled steroids > 1.5mg/day)

5. Asymptomatic Primary Hyperparathyroidism

6. Prolonged Immobilisation

Diagnosis

Dual energy XRay Absorptometry (DEXA) is the best technique for diagnosis and monitoring the response to therapy.

Management:

Principles of management

- Prevention and control of risk factors
- Management of Menopause
- Drug therapy
- Musculo skeletal and psychological rehabilitation

Control of risk factors

a. Nutrition

1. Calcium

Drink more milk. Only milk has both calcium plus other proteins which reduce bone resorption.

After menopause calcium



supplementation on a dose of 1500 mg/day is effective. Carbonate is preferred due to maximum bioavailability.

2. Vitamin D

At least 400 IU of Vitamin D should be ensured through adequate sunlight exposure.



3. Fruits and Vegetables

Fruits and vegetables are a good source of Potassium, Magnesium, Beta carotene and Vitamin D.

Such diets provide an alkaline environment and affect bone mass positively. Potassium supplements reduce urinary calcium excretion and improve bone mass.



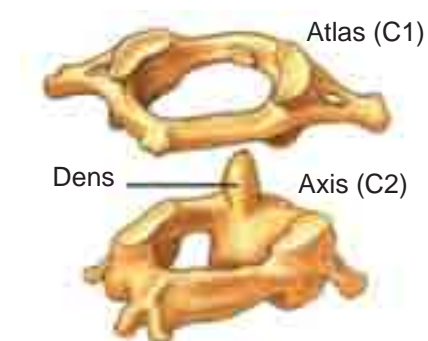
b. Lifestyle

1. Low Physical Activity leads to increased bone loss, decreased density and increased fracture risk. Exercise improves balance and co-ordination and hence reduces



Injuries of the Cervical Spine

The spine is an anatomical marvel designed to play a vital role in our well being. Any injury to our spine threatens our mobility and productivity.



their combinations act as main-injury-vectors and these are also used for classification, decision-making, and in planning for surgery.

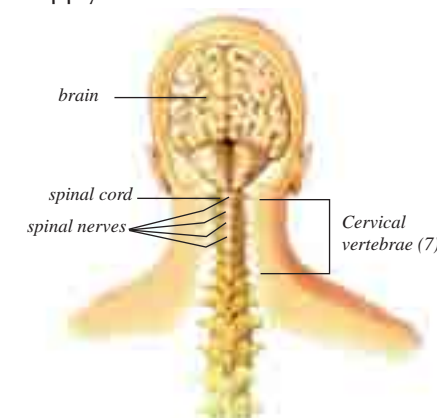
Injuries and complications

Motor vehicle accidents account for 50% of cervical spine injuries, falls, for another 20%. Sports-related activities are responsible for 15%, the remaining are attributed to interpersonal violence. The following athletic activities must be considered high risk for cervical spine lesions: Diving, horse riding, football, gymnastics, skiing, and hang-gliding.

The most feared complications of unstable cervical spine injuries are spinal cord or nerve root lesions. About 40% of cervical fractures have some degree of associated



The cervical spine has three main functions - to carry and buttress the head; to allow motions of the head in all directions and to protect the supply and communication lines



'Atlas' - according to Greek mythology, Zeus condemned the Titan Atlas to stand at the western edge of the earth and to hold up the sky on his shoulders. By analogy the first vertebra has to shoulder the head.

'Axis' - the second cervical vertebra forms the pivot (axis) upon which the Atlas rotates.

Depending on mechanism, impact of injury, compression, flexion, extension, rotation, translation and

'Form follows function' is a principle in evolution - and so the construction of the cervical spine is well adapted to fulfill these functions. Seven solid cervical vertebrae connected by intervertebral discs are joined by a complex network of ligaments and muscles, like masts and rigging of a sailing vessel.

Understanding the spine

The first two cervical vertebrae differ considerably from the other five: they have to allow the main rotation and flexion-extension of the head. Their names are well-chosen:



the number of falls and incidence of fracture. Moderate exercise. 5-10 hours per week is recommended.

2. Avoiding smoking and alcohol goes a long way in preventing osteoporosis.

3. Avoiding drugs like Steroids, Heparin and certain Anticonvulsants help increase Bone Mineral Density.

Selective Estrogen Receptor Modulators (SERM'S)

These are a class of drugs which act like Estrogen on certain organs (bone and heart) and is antiEstrogen in other areas (breast and uterus). They are particularly helpful for Spinal Fracture risk reduction with little effect on hip.

Calcitonin

This drug helps prevent bone resorption and it is particularly helpful in reducing bone pain. It reduces vertebral fracture rate by 36% It has no effect on hip fractures. Some patients develop

resistance with long term usage. Side effects are minimal but the cost is a negative factor.

Drugs increasing bone formation

Teriparatide

This hormonal preparation of Parathyroid given intermittently increases bone formation 2-3 fold and reduces fractures significantly in both Lumbar Spine and Hip. Currently it is the most potent drug available in this category. Side effects are minimal but the cost is exorbitant.

Drugs reducing bone resorption and increasing bone formation

Strontium Ranelate which is a heavy metal is the only drug in this class. Side effects are minimal.

Future Treatment

Osteoprotegerin (OPG) which is a naturally occurring protein is an inhibitor of bone resorption and is said to be useful in preventing bone loss.

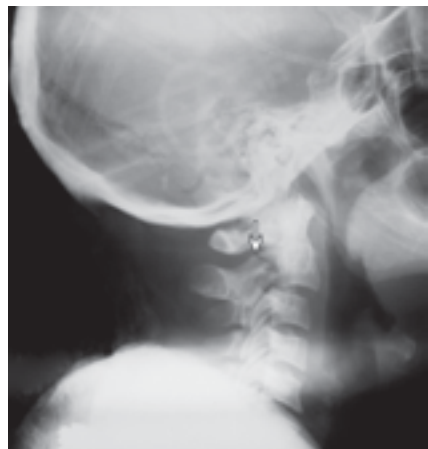
RANKL Antagonists & Antibodies, Newer Analog of Vitamin D, Insulin growth factor are some of the promising new treatment modalities.

Osteoporosis is a preventable disease. As pointed out earlier, once it sets in it is a leading cause of patient morbidity, mortality and can reduce the quality of one's life considerably. Early diagnosis, team management and enthusiastic rehabilitation go a long way in treating this dreaded disease.

Dr.S.Sridhar

Consultant Diabetologist & Endocrinologist

neurologic deficit. The risk of neurologic impairment secondary to spinal lesions increases considerably with preexisting degenerative changes of the spine. Cervical spine injuries cause an estimated 6,000 deaths and 5,000 new cases of quadriplegia each year in the USA. Death due to high cervical spine injuries usually occurs immediately from stretching of the brainstem causing respiratory arrest.



Atlas Fracture

Burst and wedge compression fractures:

Axial compression can burst the bodies of the third to seventh cervical vertebrae, or under an additional flexion vector, produce a wedge compression fracture. Both can be accompanied by a variable degree of encroachment of the spinal canal with bone.

Subluxation with unilateral or bilateral facet dislocation:

Injuries associated with flexion-rotation mechanisms lead to disruptions of the posterior ligaments with unilateral or bilateral facet dislocations.

"Whiplash" injury:

When the head snaps forward and then back again by a rear-end collision of motor vehicles it leads to a sudden distorting of the neck

with impulsive stretching of the spine, mainly the ligaments. Heavy and long-lasting symptoms may occur: Pain and aching to the neck, sensory disturbances ("pins and needles to the arm"), and headaches.

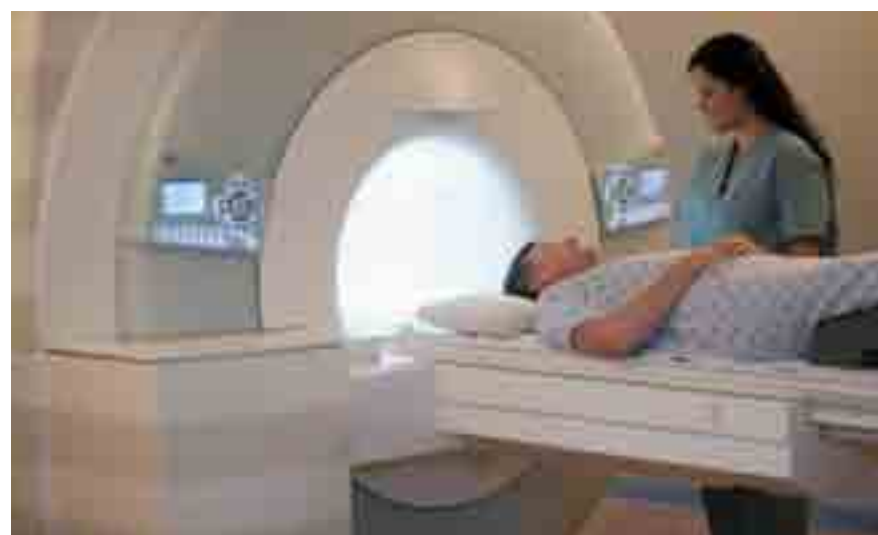Getting the diagnosis right

Exploration of history and injury-mechanism combined with a careful clinical examination must be followed by imaging studies:

Radiography with a standard trauma series composed of 5 views: cross-table lateral, swimmer's, oblique, odontoid, and anteroposterior views.

Multidetector Computed Tomography (CT Scan) is considered today as a primary diagnostic test. The American College of Orthopedic Surgeons now recommends routine cervical spine screening via CT scan instead of plain radiography.

Disco-ligamentous injuries have traditionally been evaluated by stress views under flexion and extension. MRI is less dangerous and more sensitive for soft tissue lesions than radiography.



Recommended treatment:

Today there are very few indications for conservative treatment protocols including closed reduction by skeletal traction with tongs and orthosis, Halo-vest, or Minerva plaster cast immobilization.

Operative fracture fixation after closed or open reduction of dislocations or deformities is considered as state-of-art. A real osteosynthesis however is only the screw fixation of odontoid fractures. The other fixation techniques are based on unisegmental or bisegmental fusion procedures, mostly by anterior decompression of the spinal canal, bone-grafting (with or without cages), and plating. For posterior fixation procedures there are special plate and rod systems available based on pedicle-screw-fixation.

Outcome: The main determinant is the presence or absence of an associated spinal cord injury. Early operative spine fixation facilitates active rehabilitation, which is, for patients with spinal cord injuries of paramount importance.


Professor Dr. Ottmar Trentz
Director of Accident Surgery

From Superman to Spinal Cord Victim



The most famous spokesperson for spinal cord injuries, Christopher Reeve, passed away in October 2005. Tall,

handsome and athletic Christopher Reeve shot to fame for his role as Superman. He was the epitome of masculine fitness. A sportstar and athlete, one of the many sports Reeve enjoyed was showjumping. On May 27, 1995, Christopher Reeve fell off his horse accidentally and suffered a cervical spinal injury that paralysed him from neck down. His first and second vertebrae were shattered. His head and spine were later reconnected, the first of many surgeries and procedures. A gruelling 10 years followed – but Reeve realized that he could use his name to benefit everyone with spinal cord injuries. He set up the Christopher Reeve Foundation, which supports research into spinal cord injuries. He was a spinal cord victim who was a Superman till the very end.



Spinal Surgery
and what have you got
to Show for it?

MIOT's advances in surgery allow major operations to be carried out through an opening that's as small as a keyhole.

MIOT Keyhole SURGERIES
Safe • Sure • Superior

MIOT Keyhole Surgeries include:

- Surgeries for ulcers • appendix • gall bladder • liver • spleen • pancreas
- hysterectomy • hernias • brain • lung • surgery for obesity • shoulder
- knee • spine • heart surgery



Pinhole Solutions for the Spine

Pinhole surgical treatment is possible for vertebral body compression fracture with Vertebroplasty or Balloon Kyphoplasty

When the vertebral column collapses weakened by trauma or through loading, it results in a 'vertebral body compression fracture'. These are extremely common in patients with osteoporosis. Among the many causes of osteoporosis, senile osteoporosis (due to old age) and osteoporosis due to menopause (loss of hormonal support) constitute the largest group of patients suffering from vertebral compression. Vertebral compression fractures are also found in patients with any disease that weakens vertebral bone - as in patients with cancers.

Youngsters unaccustomed to loading of the spine can also present as an acute traumatic compression fracture.

The challenge facing doctors

The treatment of vertebral compression fractures is challenging for a medical professional considering the limited options available, particularly for elderly fragile patients. Medical management of these fractures consist of bed rest, bracing, anti-osteoporotic bone strengthening medication, etc. In elderly patients these non-surgical treatments carry a high risk of multiple complications, many of which are potentially life threatening, like stroke, lung infections, heart failure, fractures above the level of collapse, etc.

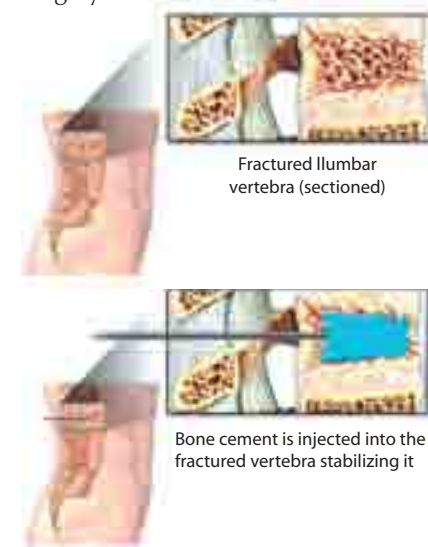
Geriatric terminally ill patients may

not tolerate the trauma of extensive open surgeries. So the million dollar question is ...

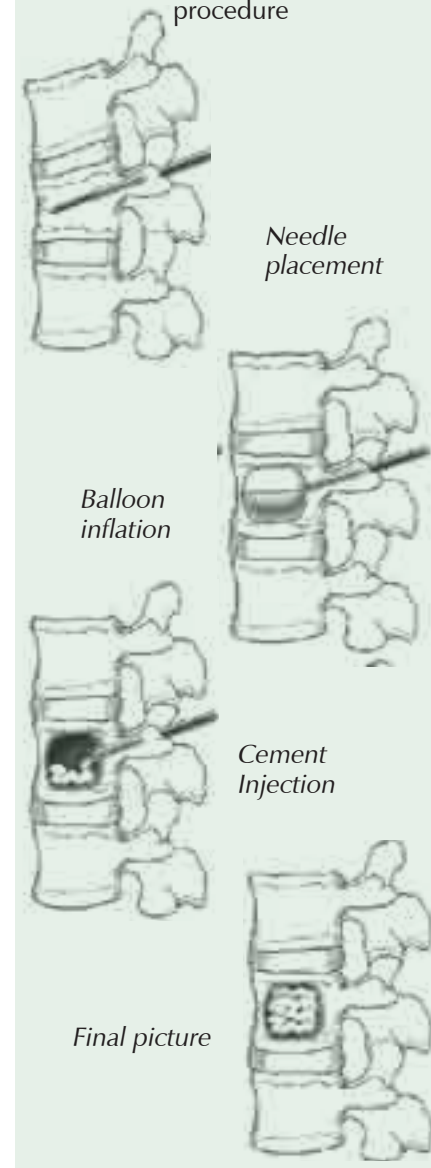
How to treat such patients?

Minimally Invasive pinhole vertebroplasty or kyphoplasty can be an answer to this delicate clinical problem. Both surgical procedures have been shown to improve the acute pain and disability associated with vertebral compression fractures without increasing the morbidity of the patient.

First performed in 1984, Vertebroplasty involves injection of bone cement into the fractured vertebral body. The procedure is performed through a pinhole approach under local anesthesia. The procedure is a day care surgical intervention wherein the patient gets relief from symptoms soon after the procedure and may be mobilized and discharged a few hours after surgery.



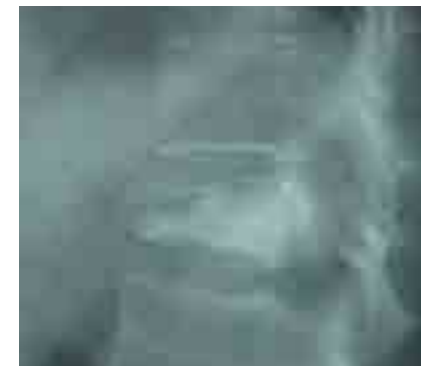Balloon kyphoplasty involves percutaneous cannulation (inserting a needle through the skin) of the fractured vertebral body, inflation of a tamp (Balloon) inside the vertebral body and the placement of the cement in the void created by the tamp. It is also performed under local anesthesia through a pinhole approach and is a day care procedure



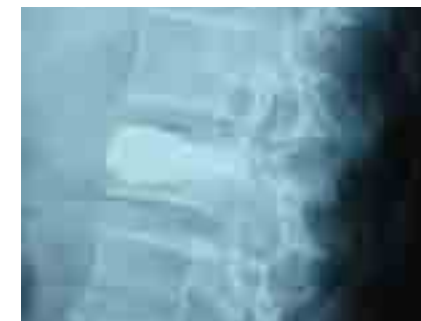Article

The results

Bone vertebral body augmentation procedures result in stabilization of the fracture and immediate pain relief. Balloon kyphoplasty differs from vertebroplasty in that the tools used to perform kyphoplasty are specifically designed to achieve correction of fracture-related angular deformity and restoration of lost body height



Pre-op



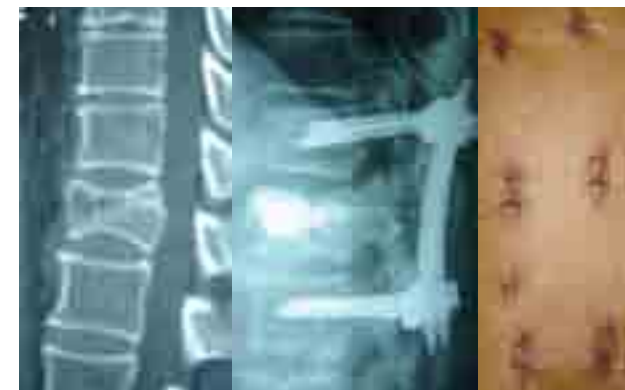Post-op

The immediate outcome for a patient is more or less the same with either procedure. There is no conclusive evidence to show a clear superiority of one procedure over the other. However, studies have shown that the risk of subsequent fracture of the adjacent or non-adjacent vertebral body is greatly reduced with kyphoplasty. This is because kyphoplasty, by correcting the deformity and restoring the height, restores the normal bio-mechanics of the human

spine. Kyphoplasty also helps to inject higher quantity of cement. Higher the cement inside the vertebral body the better the stability.

In acute traumatic burst-compression fracture:

Patients presenting with stable burst fractures (where the bone fragment is



not damaging the nerve) or acute traumatic compression fractures without nerve damage do not need conventional open surgeries. Largely, they are treated with bed rest, corsets and medications. Pain or disability arising from these fractures may warrant surgical intervention to restore a patient's normal function. To such patients, non-invasive pinhole procedures like vertebroplasty or kyphoplasty could be the best choice.

DR. NIRAJ BHUPENDRA VASAVADA
Consultant Spine Surgeon

Article

Veena lessons at 65? Why not?

Only a perfectly matched implant fitted with zero error precision can give you joint replacements that last a lifetime.



After 35 years in this field we've realized that every replacement is a special case. The hip or knee that has deteriorated due to arthritis is different from a joint that's deteriorated due to fracture. We also have to take into account the severity of the disease, the extent to which the bone has been damaged, the angle and wear and tear of the bone - all of which differ from person to person. And that's only half the picture...

No "one size fits all"

We now have to find an implant that matches all these conditions and suits your age and level of activity.

Implants come in different sizes and different materials – from chrome cobalt to titanium, from cemented to uncemented. Choosing the right one will make a crucial difference to your comfort and mobility.

Without the exactly matched implant you will experience discomfort, a change in gait and increased wear and tear that will ultimately lead to another revision surgery being needed.

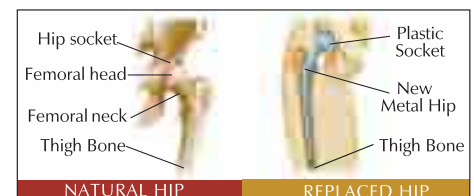
MIOT's Joint For Life

Our Joint for Life programme begins with an expert evaluation of the disease and health condition.

Next, comes selecting the implant - here we draw on our 35 years of experience and the widest range to find the perfect implant for you.

Walking tall with MIOT

The chosen implant will be fitted by an expert surgical team, using minimally invasive techniques that reduce scarring and pain.



Uncemented Hip Replacement

You will be able to walk on the same day after surgery. With physiotherapy you will return to your normal life and enjoy full activity.

Walk tall for life!

Only MIOT brings together 35 years of experience - 21,000 hip and knee replacements, largest range of implants, minimally invasive surgery, computer navigation for zero-error, infection-free environment to give you a Joint for Life.



Hip and Knee Replacement Surgeries

